

## **Traumatic Brain Injury (TBI) teaching day**

**10<sup>th</sup> June 2026**

0900 Welcome and description of TBI patient vignette	Dr Colette Griffin/Dr Akshay Nair
09 10 Patient and charity involvement post TBI	Patient/Headway
09 40 Clinical presentations of TBI: medical and nursing	Dr Colette Griffin/Isobel Herbert

### **10 05 session close followed by coffee**

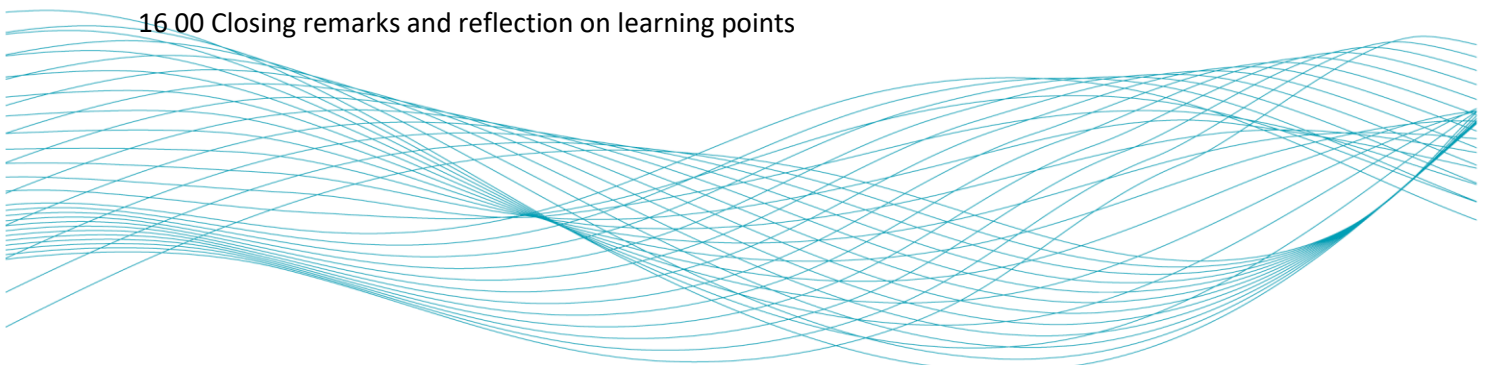
10 25 Post traumatic amnesia and cognitive changes post TBI	Jean Pring/ Patrick McKnight
10 50 Agitation and behavioural changes post TBI	Dr Akshay Nair/ Patrick
11 15 Mental capacity assessment	MCA team/Patrick/Dr Akshay
11 40 Cognitive communication post TBI	Kirsty/Jean Pring
1205 Panel discussion and Q&As	

### **12 25 lunch**

13 15 Physical neurorehabilitation post TBI	Kal Patel/Molly Bromley-Martin
13 40 Post traumatic vertigo: assessment and treatment	Dr Hena Ahmad/Kal Patel
14 05 Post traumatic headache: diagnosis and management	Dr Ivy Ong/Dr Hena Ahmad
14 30 Panel discussion and Q&As	

### **14 50 Coffee**

15 10 The overlap between mild TBI and FND	Dr Camilla Clark
15 35 Neurosurgical management of TBI	Mrs Fay Greenway
16 00 Closing remarks and reflection on learning points	



Pre- course useful reading:

Parker TD, Rees R, Rajagopal S *et al*, 2021. Post traumatic amnesia, *Practical Neurology*, Vol:22, Pages: 129-136 <http://dx.doi.org/10.1136/practneurol-2021-003056>

Head Injury for Neurologists Richard Greenwood *Journal of Neurology, Neurosurgery and Psychiatry* 2002;**73**(Suppl I):i8-i16.

During the course, we will use a case vignette as a basis for further discussion:

ME is a 29 year old lawyer, who was riding an e scooter and collided with a tree. He was brought to ED by HEMS, and intubated and ventilated due to extreme agitation. His CT scan of the brain shows bilateral frontal contusions, with surrounding oedema. He is reviewed by the neurosurgery team who advise that he is for conservative management and does not require surgery.

In addition to the traumatic brain injury, ME has sustained multiple spinal fractures, in both the cervical and the lumbar region. These have been reviewed by the spinal surgeons and the management plan is that he needs to wear a spinal brace and surgery is not indicated.

ME has been extubated, and has been stepped down to the neurology ward. He is very upset that he cannot go home, and has been e mailing his clients on his phone. He is rude to staff, disinhibited, and agitated. He is refusing to wear his spinal brace and is walking around the ward trying to leave.

He is very confused, and not orientated to time, place or person. He thinks he is in the departure lounge of terminal five. He is very clear that as a lawyer he can sign a self discharge form and be home in time for the birth of his third child.

During discussions with the ward staff ME admits to drug use and excess alcohol use, but he does not want his family or employers to be made aware of this. He lives with his wife who is expecting their first child in one weeks' time. He also has four year old twins who live with his ex partner.